

# Retraction pockets of tympanic membrane: protocol of management and results of treatment

## Protokół postępowania i wyniki leczenia kieszonek retrakcyjnych błony bębenkowej

JÓZEF MIERZWIŃSKI<sup>1/</sup>, ANDREW J. FISHMAN<sup>1,2/</sup>

<sup>1/</sup> Oddział Otolaryngologii, Audiologii i Foniatrii Dziecięcej, Wojewódzki Szpital Dziecięcy w Bydgoszczy

<sup>2/</sup> Cadence Neuroscience Institute, Winfield, Illinois USA

**Introduction.** Decisions on the procedure to be used in the treatment of retraction pockets (RP) depends on the functional and anatomic condition of the ear, but still continue to be debatable. The authors propose the protocol of the procedure to be applied for the management of RP and present the analysis of the accordingly implemented treatment.

**Aim.** To find the most appropriate way of management of atelectatic changes of tympanic membrane (TM) and analyse the results of the proposed procedure.

**Materials and methods.** Fifty nine ears of 53 patients had been followed up since 2002 till 2008. Forty nine children and 4 adults 5-36 years of age (mean 10.6) were included into the study. RP excision was performed in 8 ears, cartilage tympanoplasty in 25 ears and T-tube insertion in 26 ears.

**Results.** Primarily, in short term observations, good results were obtained in 88% of patients after cartilage tympanoplasty, 79% after T-tube insertion and 76% after excision of RP. However, further follow up revealed that, in a substantial number of T-tube patients the disorder tended to recur and required further interventions. The results after cartilage tympanoplasty were most stable.

**Conclusions.** Early use of cartilage as tympanic membrane reinforcement is indicated both in Charachon type 2 and type 3 pockets. Indications for surgery should be based mostly on anatomic status and observation of behavior of retraction pocket over time, since hearing in that disorder usually continues to be normal for a long period of time.

**Key words:** *treatment, retraction pocket, atelectatic ear, preventive tympanoplasty, cholesteatoma, cartilage tympanoplasty*

**Wprowadzenie.** Decyzje o postępowaniu w przypadku kieszonek retrakcyjnych błony bębenkowej zależą od czynnościowego i anatomicznego stanu ucha, oraz długotrwałej obserwacji, lecz wciąż budzą kontrowersje. W pracy przedstawiono propozycję protokołu postępowania w przypadku kieszonek retrakcyjnych oraz wyniki leczenia zgodnego z proponowanym protokołem.

**Cel pracy.** Przedstawienie optymalnego sposobu leczenia kieszonek retrakcyjnych błony bębenkowej wraz z analizą wyników proponowanego postępowania.

**Materiał i metody.** Obserwacja 53 pacjentów (59 uszu) w latach 2002-2008 (w tym 49 dzieci i 4 dorosłych). Wycięcie kieszonki zastosowano w 8 przypadkach, tympanoplastykę z chrząstką w 25 przypadkach, drenaż T w 26 przypadkach.

**Wyniki.** Obserwacje wczesne wykazały dobre anatomiczne wyniki leczenia u 88% pacjentów po tympanoplastyce z chrząstką, 79% po drenażu T, oraz 76% po wycięciu kieszonek retrakcyjnych. Długotrwałe obserwacje wykazały jednak, że w znaczącej liczbie przypadków po drenażu T patologia błony bębenkowej ma tendencję do nawrotu i wymaga dalszych interwencji. Wyniki po tympanoplastyce z chrząstką były najbardziej stabilne.

**Wnioski.** Wczesne zastosowanie chrząstki do podparcia atelektatycznej błony bębenkowej jest wskazane zarówno w kieszonkach retrakcyjnych typu 2 jak i typu 3 (wg Charachon). Wskazania do leczenia chirurgicznego w przewlekłym atelektatycznym zapaleniu ucha powinny być ustalane przede wszystkim na podstawie anatomicznego stanu kieszonek oraz obserwacji progresji patologii, ponieważ słuch w chorobie tej najczęściej przez długi czas pozostaje prawidłowy.

**Słowa kluczowe:** *leczenie, kieszonki retrakcyjne, ucho atelektatyczne, tympanoplastyka prewencyjna, perlak, tympanoplastyka z chrząstką*

## Introduction

The retraction pocket (RP) of tympanic membrane (TM) is a pathological invagination of tympanic membrane into the middle ear space. It is usually regarded to be a sequel of chronic otitis media with effusion [1-3]. Prolonged dysfunction of the Eustachian tube and excessive negative pressure in the middle ear may lead to atrophic changes in the middle, fibrous layer of tympanic membrane and to development of localized or generalized TM atelectasis. The most common sites of RP are pars flaccida and postero-superior parts of TM [4]. Progression of the retraction causes the atrophic membrane to drape over the incus and stapes, often resulting in necrosis of these ossicles (Fig. 1). Over time RP tend to form adhesions with the surrounded structures, which make changes irreversible. Another problem is that some of deep RP loses ability to self cleaning and starts to accumulate debris and epithelium which are prone to infections. Infected pocket with debris and granulous tissue may be regarded as pre-cholesteatoma [5].

Some of RP will regress spontaneously, some will remain stable, and some will proceed and will lead to cholesteatoma formation [6]. Apart from Eustachian tube dysfunction there were also some suggestion that the process is due to the presence of fluid and inflammatory process in the middle ear followed by activation of collagenase and other enzymes in TM which causes breakdown of its fibrous layers [7].

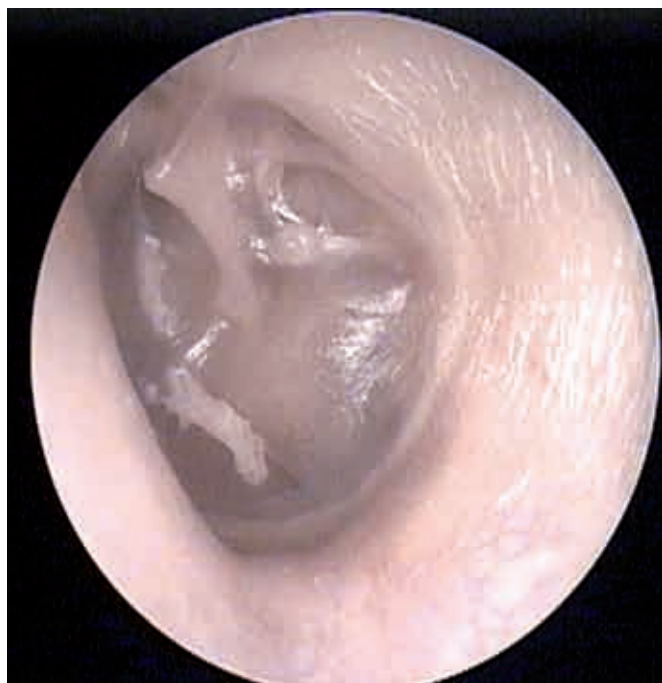

Fig. 1. Retraction pocket draped over incus and stapes with necrosis of long crus of incus

The difficulties in decision making about surgical treatment of RP are related also to the fact that both at early and in advanced stages the symptoms can be rather minimal, and hearing even after destruction of the long process of incus may remain almost normal. The decision about aggressive surgical treatment is not a problem in a patient with significant conductive hearing loss, but it is especially difficult in patient with normal hearing. This kind of surgery is called preventive tympanoplasty [8].

Early intervention in the ear with not significant destruction is technically much easier to perform. However there is always a risk of hearing deterioration and other complication in the ear with minor pathology which could possibly stabilize it in the future without intervention. On the other hand “wait and see” policy “may lead to extent adhesions in the middle ear what will end cause difficult surgery and possibly negatively influence final result of the treatment.

In this paper long term results of treatment of RP will be shown, according to algorithm of retraction pocket management used by author which also will be presented [9,10].

## Diagnostic considerations

Each patient with RP should have a thorough examination of nose and nasopharynx, adenoid should be removed if present, allergy excluded /or treated. If nose patency is disturbed, antihistamines and other decongestant are advocated. Each patient should be advised to use auto inflation training.

The ear should be thoroughly cleaned of cerumen and debris, since RP is often hidden behind them. RP may be found at any place of TM. **Oto-microscopy** is mandatory and in case when the bottom of RP cannot be seen otoendoscopy with angled optic are useful.

**Pneumatic otoscopy** is essential in establishing whether pocket is reversible (movable or fixated). Patient may be also asked to perform Valsalva maneuver to inflate middle ear while otoscopy.

**Audiometry** is very important, when air bone gap is significant all cases should be considered for treatment.

**Tympanometry** is helpful in establishing whether RP is accompanied by middle ear fluid presence.

**CT of the temporal bone** is indicated especially in deep (type 3) RP where the bottom cannot be seen.

One of the most important issues in RP diagnosis is **systematic follow up** of the patient with assess-

ment of progression of the disease over time. We recommend check every three months, with photo documentation, or exact anatomic notes / drawings for better comparison.

There are three main questions which should be addressed before decision making.

- What is anatomic status of the retraction pocket?
- What is functional status of the ear (hearing)?
- What is a behavior of RP over a time?

Anatomic status of retraction pockets has been a subject of several studies. The number of different classifications is the best evidence of complexity of the problem. The best known are that of Sade, Tos and Charachon [3,11,12]. Practically we implied some modification of the Charachon system which is not ideal but reflects the most important features of RP, necessary for the decision making.

At first one has to address whether RP is located in pars tensa, or pars flacida of TM. The reason of it is that the flaccid part of TM has no fibrous layer, so the RP development is quicker, followed by quick bone absorption, and faster formation of cholesteatoma. In these cases the management should be more aggressive. Important for evaluation is whether it is possible to see with the microscope the extent of RP and to evaluate whether there is no debris at the bottom. Depending on whether it is possible to see all parts of the pocket or not it is called controllable or incontrollable RP.

Other important feature is whether the RP is fixated or not. Those which are adhered to the middle ear structures but cannot be reversed are called fixed. The one which adheres to the ossicles and promontory but can be reversed is called not fixed.

Reassuming RP can be classified as:

Type 1: controllable, not fixed (Fig. 2)

Type 2: controllable, fixed (Fig. 3, 4, 5)

Type 3: incontrollable, fixed (Fig. 6)

We introduced our personal modification of the Charachon grading system by adding letters F in cases where flacid part of TM is involved, or letter T in cases where tense part is involved. Taking all the features we can address any kind of RP as for ex: F1 (flaccid part controllable, not fixed RP), or T3 (tens part incontrollable, fixed RP).

Important issue that should be considered while decision-making is whether effusion coexists with RP and what is the hearing status of the patient.

The majority of RP which are seen in adults or older teenagers are the remains from childhood when substantial dysfunction of ET was present, most often accompanied by otitis media with effu-

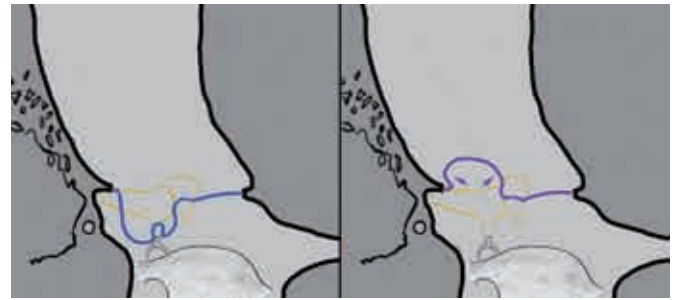


Fig. 2. Retraction pocket type 1 before and after inflation: controllable, not fixed (Fig. A.J. Fishman)

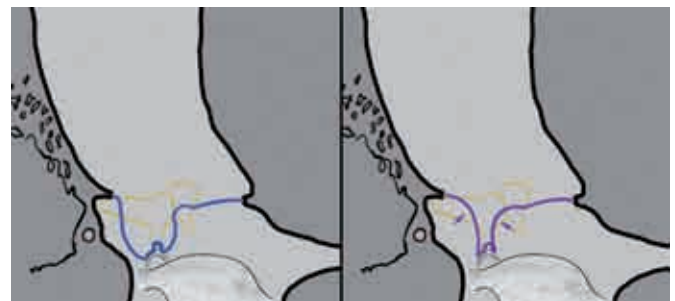


Fig. 3. Retraction pocket type 2 before and after inflation: controllable, fixed (Fig. A.J. Fishman)

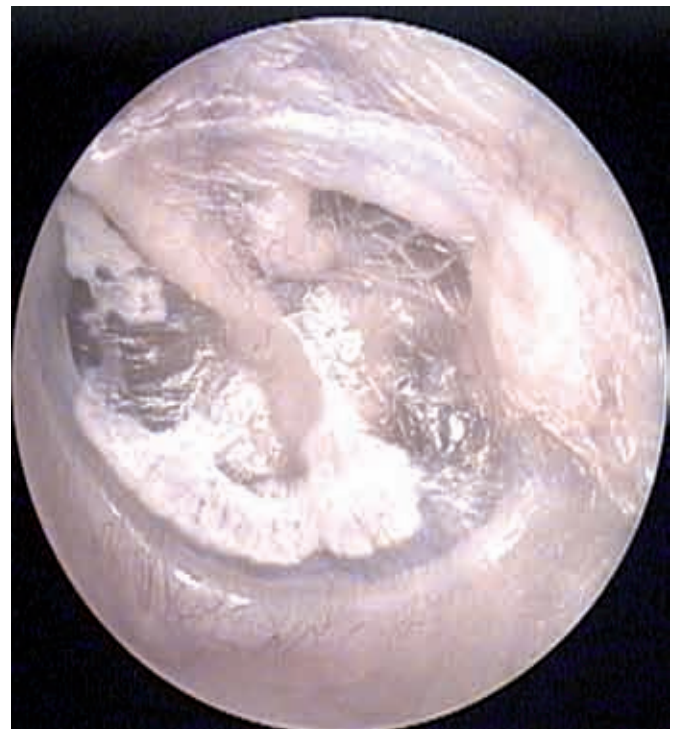

Fig. 4. Retraction pocket type 2 before inflation

sion. At some point such RP stabilized and did not develop any more. If the hearing does not exceed 20dB Air Bone Gap (ABG) these RP should not be treated. In some individuals however RP progressively proceeds to form adhesions and finally cholesteatoma. If there is rapid progression over time,

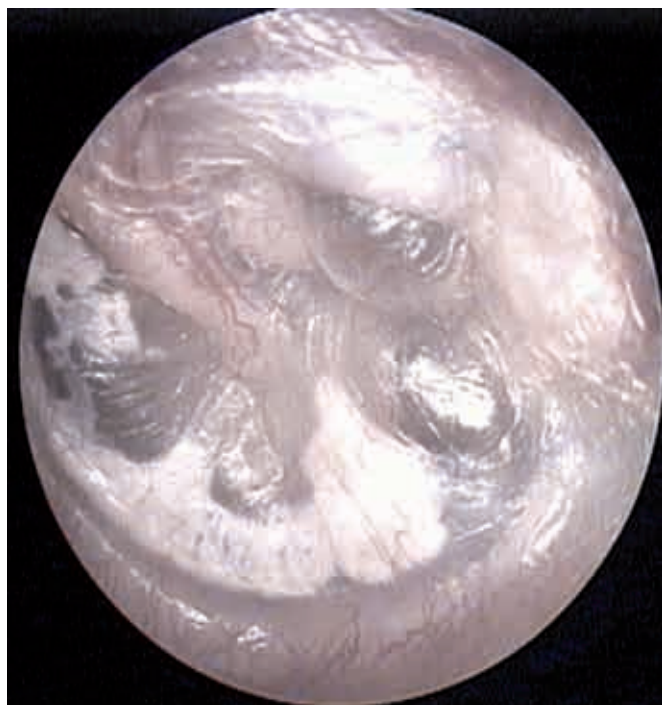

Fig. 5. The same retraction pocket type 2 after inflation

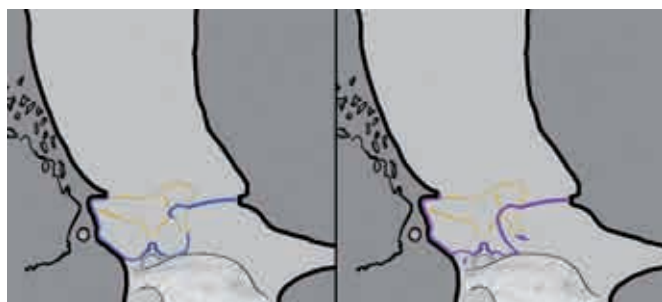


Fig. 6. Retraction pocket type 3 before and after inflation: uncontrollable, fixed (Fig. A.J. Fishman)

such RP obviously should to be treated in order to prevent progression to more advanced stages.

If retraction pocket is accompanied by chronic middle ear effusion it can be regarded as a proof of an active process in the middle ear. Long lasting fluid together with negative tympanic cavity pressure causes secondary changes of TM. Such a case should be treated without any delay.

The evolution of RP to secondary acquired cholesteatoma is a well proved phenomenon [6,12]. However some controversy exists about the borderline between deep uncontrollable and non reversible retraction pocket and cholesteatoma. It seems to be logical that if RP is filled with debris and cerumen (precholesteatoma) it means that self cleaning properties of TM are lacking in that case and the decision about surgery should be quicker. If RP is filled with debris, infected and perforated, it is already a cholesteatoma.

## Management protocol

### Stage 1 RP

Wait and see policy can be implemented provided that there is no hearing loss exceeding social communication problems (20dB ABG), and that there is no chronic middle ear effusion. If after three months no progression is observed patient is followed up every three months, for two years. If progression of RP is noted, or if there is a significant hearing loss, and /or OME, the patient is submitted to tympanostomy tube placement, and /or excision of RP. This interesting technique has been described first by Marquet in 1996 – after insertion of ventilating tube he advised progressive suction of the atelectatic tympanic membrane to convert the retraction pocket into lateral epithelial sac, and then cutting of the everted RP. According to his description in less than 8 days the tympanic membrane regains normal appearance [13].

It is reasonable not to excise to large areas of TM since large perforation may persist. Excision should better be done if retraction is limited to one quadrant. Pars flaccida RP are not excised since there is a risk of in growth of squamous epithelium and cholesteatoma formation at that area.

### Stage 2 RP

If there is no hearing loss, middle ear fluid or progression of RP over time “wait and see policy” is recommended. In case of hearing loss, fluid or progression we recommend subannular T-tube for ventilation and cartilage for TM reinforcement. Intracanal approach is used. After elevation of tympanomeatal flap and separation of middle ear adhesions subannular T-tube with cartilage TM support is inserted. One or two pieces of cartilage are inserted between “leg” of T-tube and atelectatic tympanic membrane to reinforce it. Initially we advocated separation of adhesions and subannular T-tube only (Fig. 7).

At our primary observations T – tube insertion in those cases warranted up to 77% success rate but in further observation results dropped, so at present we recommend T-tube and cartilage TM support (Fig. 8). Simultaneous insertion of T-tube and cartilage TM support seems to be the best option, because even if tube extrudes or is removed cartilage still prevents against progressive atelectasis. Several other authors at this stage of RP also recommend cartilage tympanoplasty treatment [4,14]. Blayney [15] recommends excision in case of fixed, stage 2 pockets together with grommet insertion for prolonged ventilation of the middle ear.

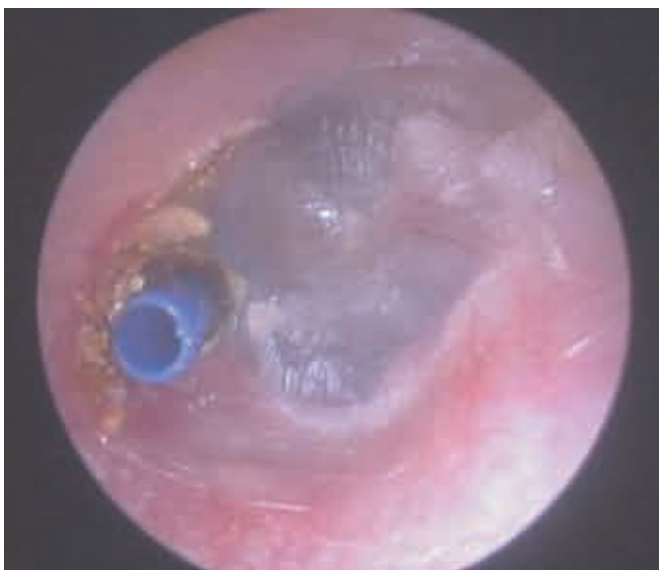

Fig. 7. Ear after subannular T-tube insertion

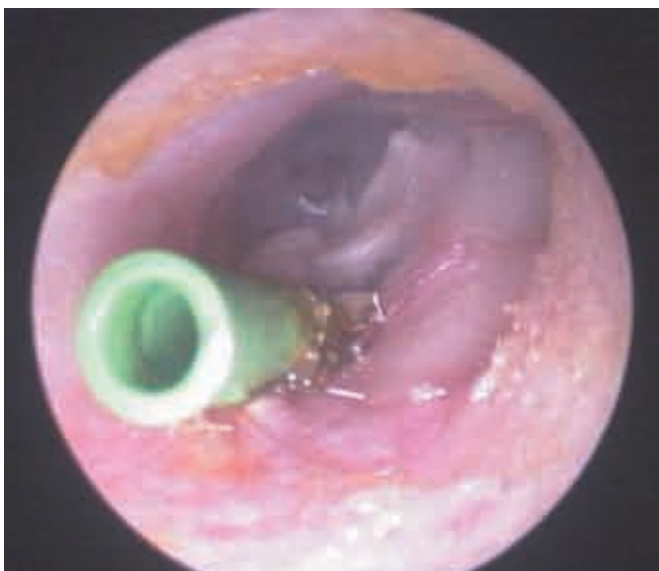

Fig. 8. T-tube at place with cartilage tympanic membrane reinforcement in the place of previous t2 retraction pocket

In case of attic retraction (F2 RPs) the atelectatic membrane should be elevated or excised and cartilage scutum reconstruction should be performed.

### Stage 3 RP

In case of uncontrollable RP most authors advocate cartilage tympanoplasty [16-18]. Surgery should be performed in order to prevent cholesteatoma formation. The RP should be separated, elevated and supported with cartilage graft. We recommend temporal bone CT scan in order to assess the extent of RP before surgery. In more extent cases combined approach tympanomastoidectomy with posterior tympanotomy is usually required with or without

ossicular reconstruction. Posterior tympanotomy is important for elevation of RP from posterior parts of tympanic cavity (facial recess, incudostapedial joint). If RP is ruptured during surgery, second look surgery should be planned in the future to exclude residual cholesteatoma. After elevation of tympanomeatal flap and evertion of pocket temporal fascia or perichondrium is inserted under atelectatic TM and one or two pieces of cartilage is inserted between fascia and TM. This gives good stabilization of cartilage. We prefer two small than one big piece of cartilage. It is easier to put in required position and hearing loss and fixation is unlikely. If middle ear effusion is found, tympanostomy tube placement should be additionally performed.

The decision about surgery should be prompted when RP is not self cleaning and debris and epithelium are found inside (risk of cholesteatoma).

If hearing is good and total atelectasis with adhesion of TM to promontory is found, with minimal chances for successful separation of RP, then observation with temporary cleaning of debris from RP and temporary imaging of the ear is advocated. Overview of the protocol is presented in table I.

Table I. Overview of strategy of retraction pocket (RP) management

Status of retraction pocket (stage 1,2,3)	Management
1	Observation, medical management, if progression or fluid or hearing loss >20 dB ABG – T-tube insertion / and or excision of RP.
2	Observation, medical management, if progression of fluid or hearing loss >20dB ABG – separation of adhesions and T-tube insertion with cartilage support of atelectatic tympanic membrane (intracanal approach).
3	Cartilage tympanoplasty (usually postauricular approach, tympanomastoidectomy with posterior tympanotomy), if fluid – tube placement.
	In cases with total atelectasis and good hearing <20dB ABG – a follow up, ear cleaning, wait and scan.

ABG – air-bone gap

## METHODS

A series of patients with deep type 1, type 2 and type 3 RPs who were treated according to above mentioned protocol is presented. Ears with minor pathology where only grommet has been inserted were excluded from the study.

Patients have been submitted to surgery such as: RP excision, T-tube, cartilage tympanoplasty. 59 ears in 53 patients have been observed since 2002.

Examination and data from the whole group were analyzed firstly in 2005 and then in 2008. There were 49 children and 4 adults.

Age of patients varied between 5-36 with mean 10.6. Number and type of RPs treated are presented in table II.

The most common were T2 RPs (table II).

Table II. Number and type of retraction pockets treated

Type of pocket	T1	F1	T2	F2	T3	F3
Number of ears	7	3	26	6	14	3

21 and 23 patients have been previously treated with grommet and adenoidectomy respectively.

Pocket excision have been conducted in 8 ears, T-tubes in 26 ears and cartilage tympanoplasty in 25 ears (table IV). Follow-up from 5 to 8 yrs (mean 5.3).

Audiogram preoperatively and postoperatively were taken in all the patients, unfortunately speech reception threshold test was not possible to perform in all patients (children) so we were not able to calculate it. Hearing results were estimated by pre- and postoperative air bone gab (ABG) taken in 2005 and 2008. ABG was established as pure tone average at the frequencies of 0,5 1,0 2,0 and 3,0 kHz. The ABG is the four pure tone averages for air conduction minus four pure tone averages for bone conduction.

**RESULTS**

In 19 (35,84%) patients preoperative audiogram did not exceeded 20 dB ABG.

Audiological data pre and postoperatively (2005 and 2008 ) are presented in table III.

In all groups overall significant hearing improvement was noted between preoperative ABG

Table III. Audiological data pre and postoperatively (2005 and 2008). ABG – average air bone gap 0,5; 1,0; 2,0; 3,0 kHz

Audiologic data	All patients N= 59	Pocket excision N=8	T-tube N=26	Cartilage tympanoplasty N=25
Preop ABG (dB)	28,6	25,8	28,7	33
SD	11,4	7,9	12,7	9,07
Postop ABG	18,7	15,5	19,8	18,7
2005 SD	7,08	6,2	6,5	6,12
Change in ABG	9,9	10,3	8,9	14,3
Postop ABG	17,1	18,31	22	15,75
2008 SD	6,79	7,1	7,3	9,2
Change in ABG	1,6	-2,81	-2,2	3

and postop ABG 2005 (p< 0.0001). There was also significant change between preoperative ABG and postop ABG 2008 (p< 0.0001). The ABG did not changed significantly between 2005 and 2008 in our patients (p = 0.17). No sensorineural hearing loss (bone conduction less that 10 dB) has been observed in the group pre- and postoperatively and no changes between pre- and postoperative bone conduction was noted.

Since in this group there were no ossicular pathology hearing status was moderated mostly by presence or absence of fluid. In postoperative group some of the patients either had no fluid already or still had T-tubes or grommets so hearing improvement was significant.

**Cartilage tympanoplasty – 25 patients**

Flaps and cartilage intake were noted in all patients, no significant hearing deterioration was observed

Till 2005 in 3 patients (12%) retractions around inserted cartilage occurred (T1 RP) which required additional ventilation with T-tube

In later follow up (2008) in one patient (4%) further severe retraction of TM (T2 RP) was observed and cartilage was inserted under remained parts of tympanic membrane.

Good results in this group reached initially 88 % and dropped to 82 % after another three years. In this group results were the most stable (table IV). In spite of advanced pathology in this group no cholesteatoma developed.

**T-tube insertion – 26 patients**

Till 2005 in 5 (19%) patients after removal/extrusion of T-tube progression to type 2 was observed and cartilage tympanoplasty has been performed.

In one patient (4%) who did not show to follow up for 2 years after T tube extrusion, RP developed to real infected cholesteatoma.

At second examination (2008) in another 5 patients (19%) progression to type 2 pockets occurred and cartilage tympanoplasty has been performed with further good result

Initially good result was obtained in 77% of patients but over time this data dropped to 58% and thus 42 % of patients required cartilage TM support (tab. IV).

**RP excision - 8 patients**

Till 2005 in one patient (12%) after excision of a RP in anterior-superior quadrant remained persisted perforation. After 5 years the perforation was closed with a use of cartilage without further problems. One patient (12%) after initially good

anatomical result developed to T2 RP and cartilage tympanoplasty was performed with further good result.

In later (2008) follow-up one more patient (12%) developed progressive RP and also required additional ventilation and TM support.

After RP excision success initially was obtained in 76% of patients, in second examination good result dropped to 64% and thus 36% of patients required further treatment (tab. IV).

Table IV. Results of cartilage tympanoplasty, subannular T-tube insertion with separation of adhesions and retraction pocket (RP) excision in the treatment of TM atelectasis. Short-term observation made in 2005 and long-term observation made in 2008.

Method of treatment N – number of patients	Success rate in short and long-term observation Number of patients		Further treatment in short and long-term observation Number of patients	
	2005	2008	2005	2008
	[%]	[%]	[%]	[%]
Cartilage tympanoplasty N=25	22 (88%)	21 (82%)	3 (12%)	4 (18%)
T-tube N=26	20 (77%)	15 (58%)	6 (23%)	11 (42%)
RP excision N=8	6 (76%)	5 (64%)	2 (24%)	3 (36%)

Overall surgical treatment of advanced atelectasis proved to be effective in 58-82 % of patients (tab. IV).

## DISCUSSION

In 1995 Chiossone (4) proposed the term preventive tympanoplasty what meant surgery of ear with good hearing but with progressively developing pathology in form of RP potentially leading to cholesteatoma formation. It meant that main indication for surgery was not hearing status as it was traditionally agreed, but anatomical state of middle ear pathology, which tended to progress over time. Minor changes of TM usually did not produce substantial hearing loss. Chiossone in case of RPs separated adhesions, and put guitar-shaped silastic which has been inserted to middle ear cavity under tympanomeatal flap and annulus tympanicum. In future the silastic could be removed without major middle ear intervention since the end of silastic was everted in external auditory canal. In major RPs he removed the pocket and performed overlay myringoplasty with perichondrium.

Successful preventive tympanoplasty means prevention of cholesteatoma formation and in experienced hands should not cause hearing deterioration, but improvement. In our algorithm we suggest to use T-tube instead of silastic. T-tube may act both as a middle ear separator but additionally improves usually poor middle ear aeration what is very important in this group of patients. After years however T-tube will finally extrude or will be removed and according to our observation substantial number of RP will return.

Looking at the patients with RPs hearing is not the main issue since in many cases of chronic atelectatic otitis media in spite of advanced middle ear pathology it remains normal or almost normal for the long time. Taking hearing status only as the indication for surgery is also not proper, since this will often lead to postponing of surgery and to cholesteatoma formation or advanced adhesions, difficult for successful surgical correction. In preventive tympanoplasty criteria for surgery should include meticulous follow up of the patient over time. In cases where the progression is observed management should be implemented according to the protocol.

In this group we did not included patients with ossicular damage so the hearing loss was usually not very significant, and caused mostly by presence or absence of middle ear fluid.

In presented cases results can be regarded as satisfactory but it should be stressed that treatment of RP is a dynamic process and surgery does not mean the termination of treatment. Active dysfunction of ET may still be present in these patients and pathology may return. This may require additional interventions facilitating ventilation of middle ear and/or TM reinforcement. As it was showed the anatomic status of some ears was changing over time. Initially we treated type 2 pockets with T-tube alone in follow up we noticed that the rate of success from 77% in 2005 dropped to 58% 3 years later. Cartilage tympanoplasty gave much more stable results so as it was showed the protocol is now changed.

Some of the data may change after further follow up since even 5 years observation period may not be sufficient for final result in this specific ear disease. Some assumptions of presented retraction pocket management may thus be modified in the future.

## CONCLUSIONS

1. Preventive tympanoplasty gives good anatomical results in patients with progressive atelectasis of tympanic membrane and in experienced hands should not cause hearing deterioration but improvement
2. Indications for surgery should be based mostly on anatomic status and progression of retraction pocket over time since hearing is frequently normal for the long time
3. In progressively developing retraction pockets type 2 early cartilage TM reinforcement gives better results than T-tube alone
4. Formation of retraction pocket is dynamic process and patients after initial surgery should be followed up and may require additional interventions in the future.

## Piśmiennictwo

1. Li Y, Hunter LL, Margolis RH, Levine SC, Lindgren B, Daly K, Giebink GS. Prospective study of tympanic membrane retraction, hearing loss, and multifrequency tympanometry. *Otolaryngol Head Neck Surg.* 1999; 121(5): 514-22.
2. Maw AR, Bawden R. Tympanic membrane atrophy, scarring, atelectasis and attic retraction in persistent, untreated otitis media with effusion and following ventilation tube insertion. *Int J Pediatr Otorhinolaryngol.* 1994; 30(3): 189-204.
3. Sade J, Berco E. Atelectasis and secretory otitis media. *Ann Otol Rhinol Laryngol.* 1976; 85(2 Suppl 25 Pt 2): 66-72.
4. Ars BM. Tympanic membrane retraction pockets. Etiology, pathogeny, treatment. *Acta Otorhinolaryngol Belg.* 1991; 45(3): 265-77.
5. Akyildiz N, Akbay C, Ozgirgin ON, Bayramoglu I, Sayin N. The role of retraction pockets in cholesteatoma development: an ultrastructural study. *Ear Nose Throat J.* 1993; 72(3): 210-12.
6. Wells MD, Michaels L. Role of retraction pockets in cholesteatoma formation. *Clin Otolaryngol Allied Sci.* 1983; 8(1): 39-45.
7. Granstrom G, Holmquist J, Jarlstedt J, Renvall U. Collagenase activity in middle ear effusions. *Acta Otolaryngol.* 1985; 100(5-6): 405-13.
8. Chiossone E. Preventive tympanoplasty in children: a new approach. *Rev Laryngol Otol Rhinol (Bord)* 1995; 116(2): 137-9.
9. Mierzwiński J, Fishman AJ. Przewlekłe atelektatyczne zapalenie ucha środkowego. (w) *Otolaryngologia Dziecięca.* Danuta Gryczynska (red.). Alfa-Medica Press, Bielsko-Biała 2007: 104-10.
10. Mierzwiński J, Fishman AJ. Retraction Pockets, Treatment Algorithm. (w) *Encyclopedia of Otolaryngology, Head and Neck Surgery.* Stilianos E. Kountakis (red.). Springer 2013: 2276-83.
11. Charachon R. Classification of retraction pockets. *Rev Laryngol Otol Rhinol (Bord).* 1988; 109(3): 205-207 [French].
12. Tos M, Stangerup SE, Larsen P. Dynamics of eardrum changes following secretory otitis. A prospective study. *Arch Otolaryngol Head Neck Surg.* 1987; 113(4): 380-5.
13. Marguet J. Preventive treatment of cholesteatoma. *Impharzam Medical Forum* 1986; 9: 23-7.
14. Lacher G. Pre-cholesteatoma status *Rev Laryngol Otol Rhinol (Bord)* 1988; 109(3): 223-9.
15. Blaney SP, Tierney P, Bowdler DA. The surgical management of the pars tensa retraction pocket in the child-results following simple excision and ventilation tube insertion. *Int J Pediatr Otorhinolaryngol* 1999; 50(2): 133-7.
16. Couloigner V, Molony N, Viala P, Contencin P, Narcy P, Van Den Abbeele T. Cartilage tympanoplasty for posterosuperior retraction pockets of the pars tensa in children. *Otol Neurotol.* 2003; 24(2): 264-9.
17. Levinson RM. Cartilage-perichondrial composite graft tympanoplasty in the treatment of posterior marginal and attic retraction pockets. *Laryngoscope* 1987; 97(9): 1069-74.
18. Poe DS, Gadre AK. Cartilage tympanoplasty for management of retraction pockets and cholesteatomas. *Laryngoscope* 1993; 103(6): 614-8.
19. Dornhoffer JL. Surgical management of the atelectatic ear. *Am J Otol.* 2000; 21(3): 315-21.
20. Wolfman DE, Chole RA. Experimental retraction pocket cholesteatoma. *Ann Otol Rhinol Laryngol.* 1986; 95(6 Pt 1): 639-44.